

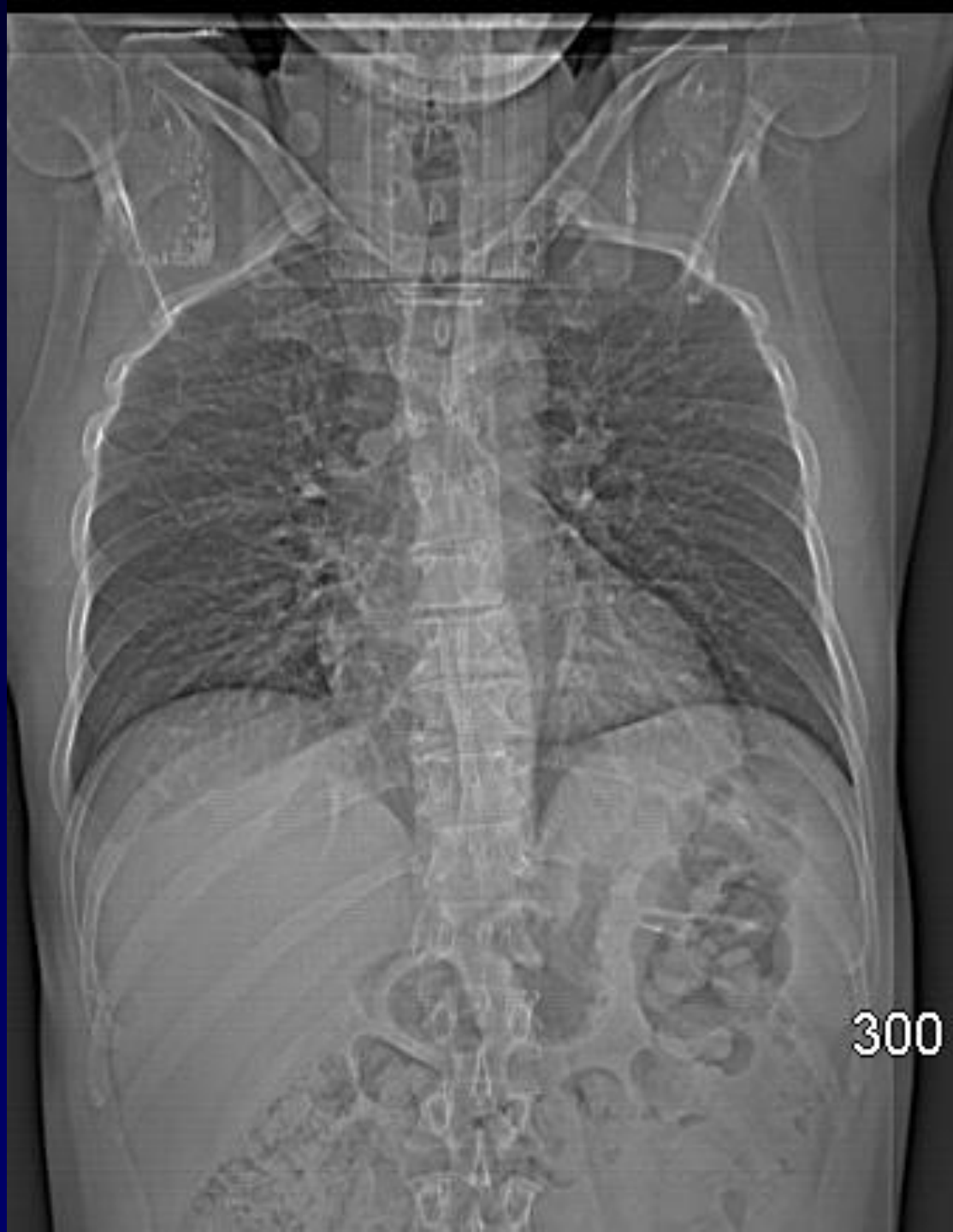

**J-GIRON – P-FAJADET**

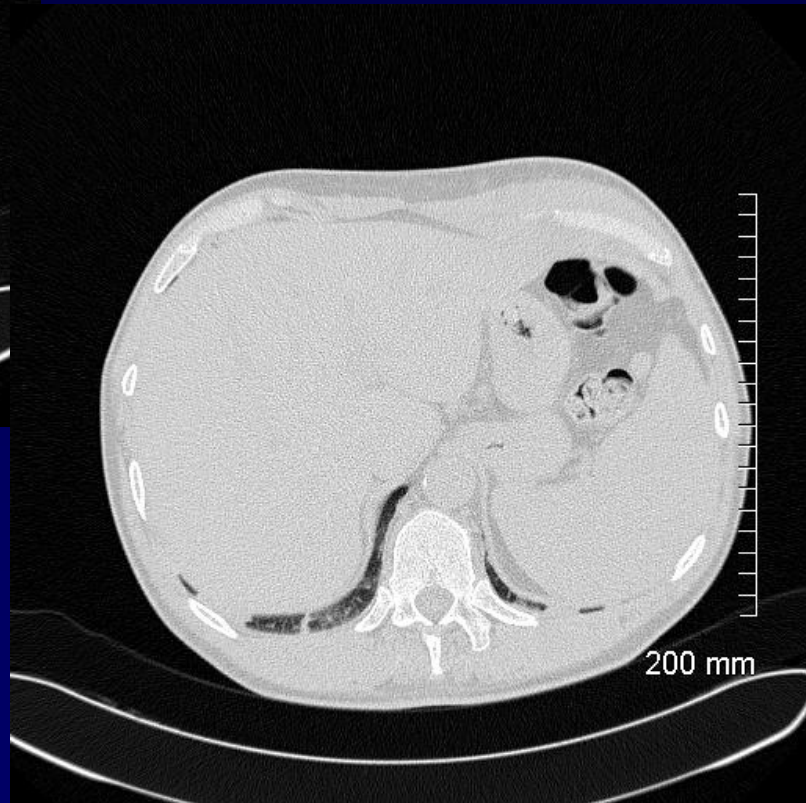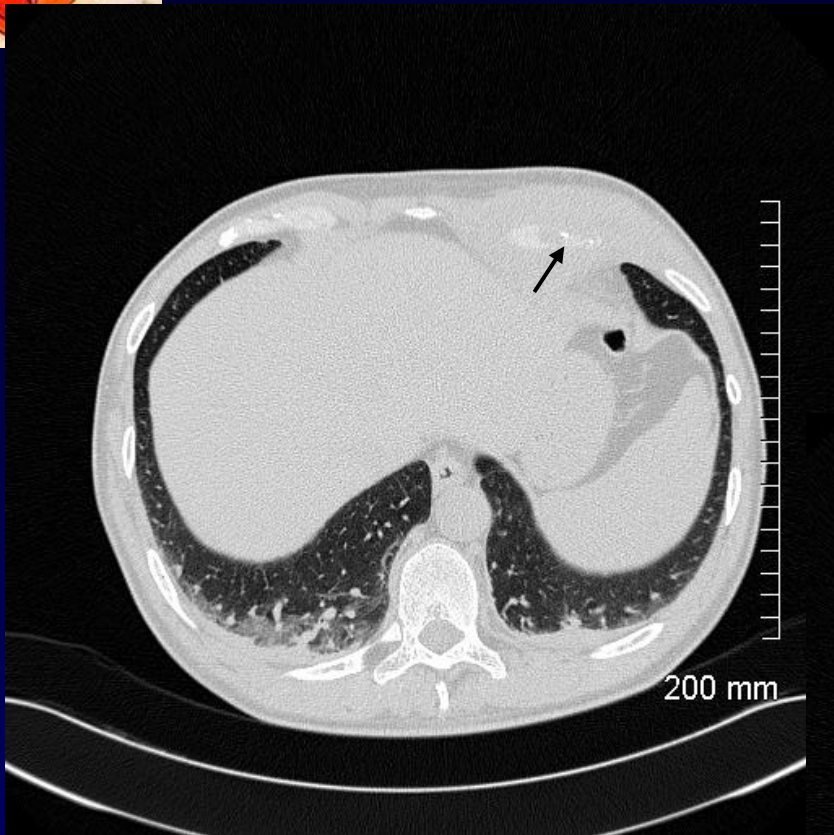
Homme de 45 ans

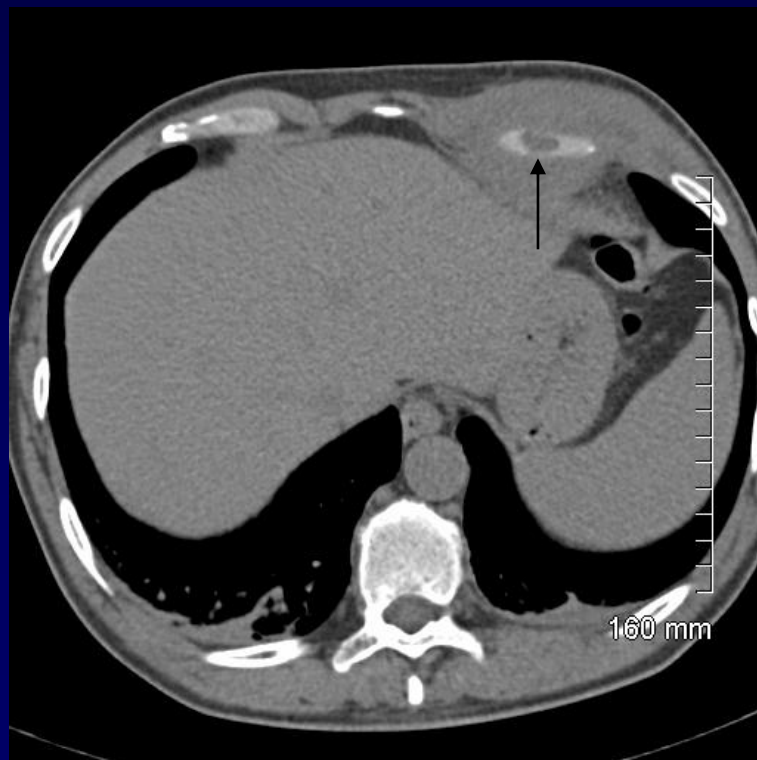
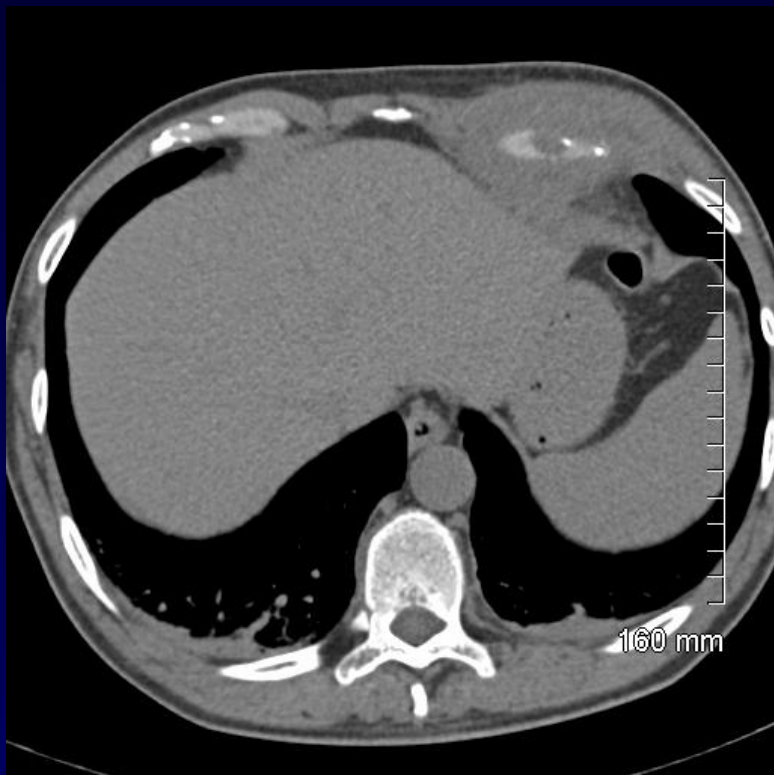
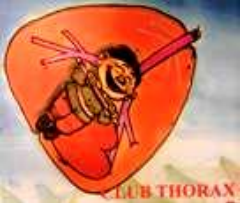Tuméfaction de paroi après choc ...minime .

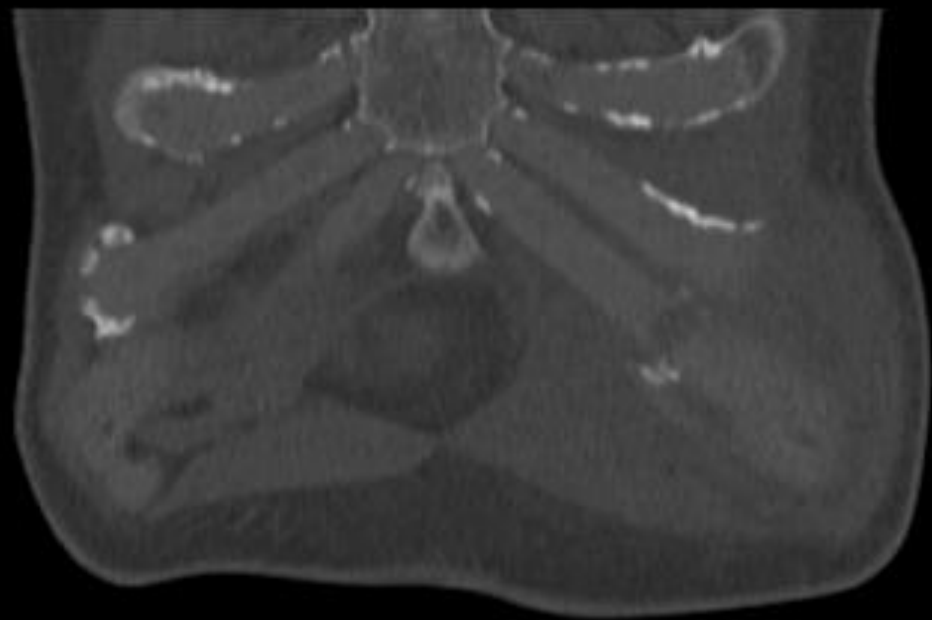
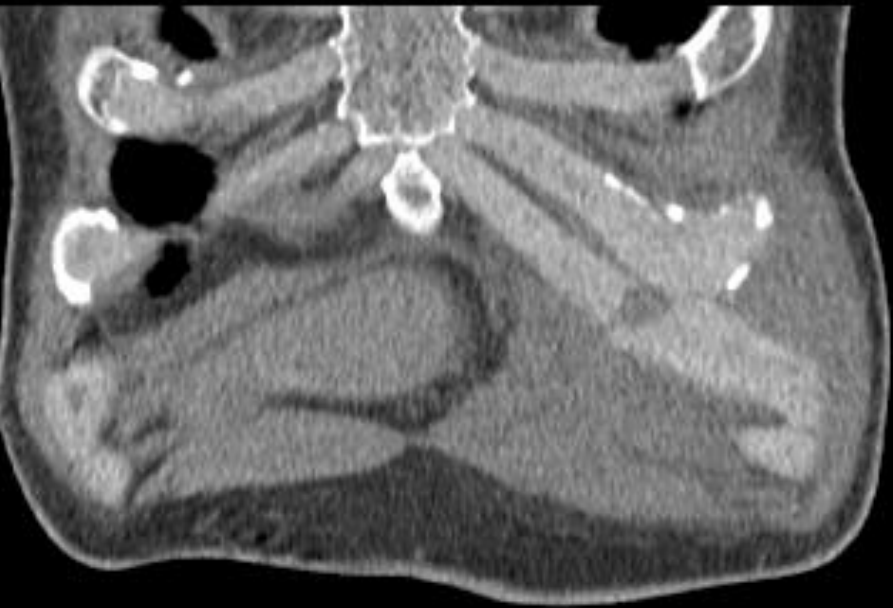
Sujet VIH

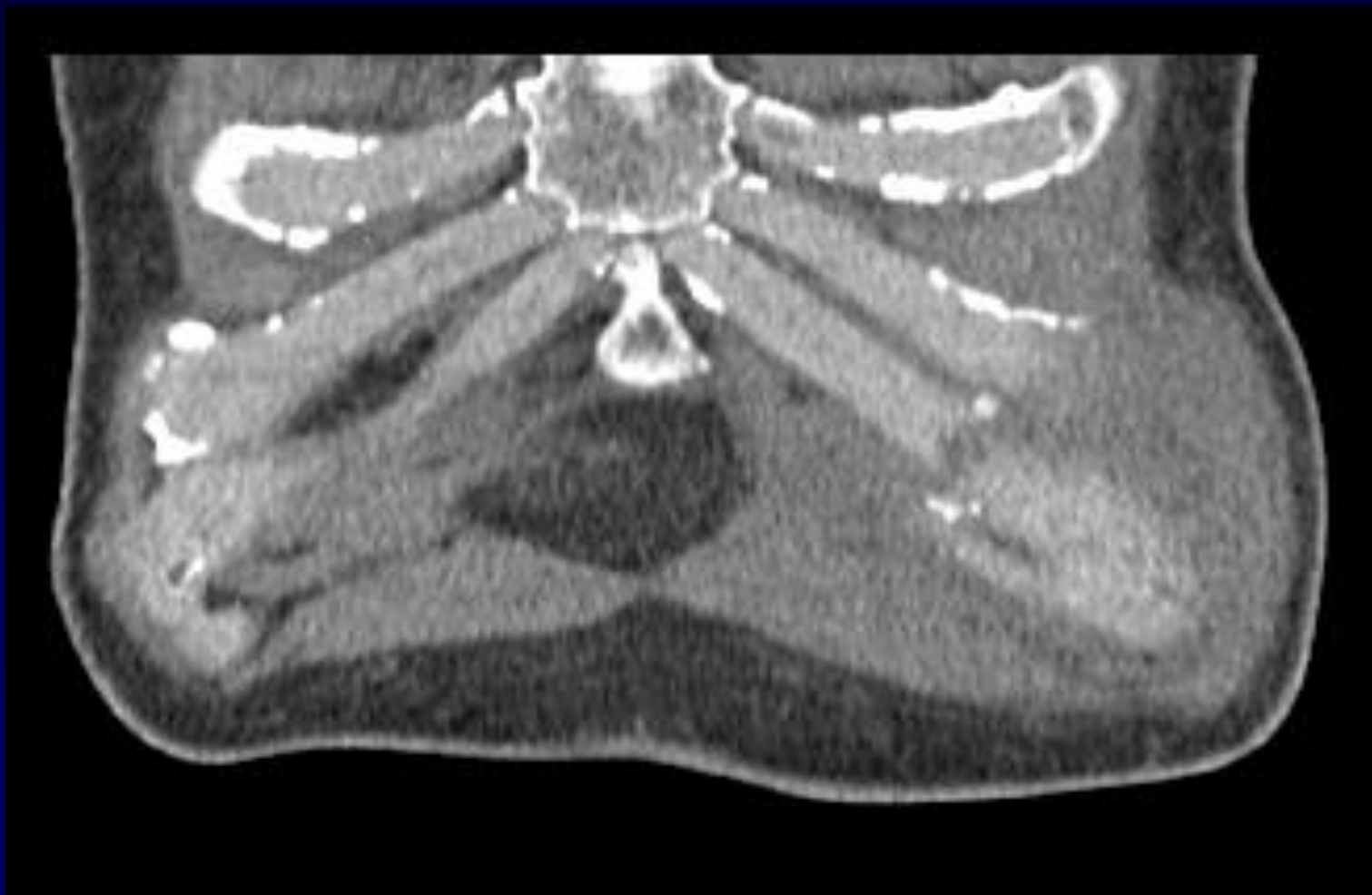

300



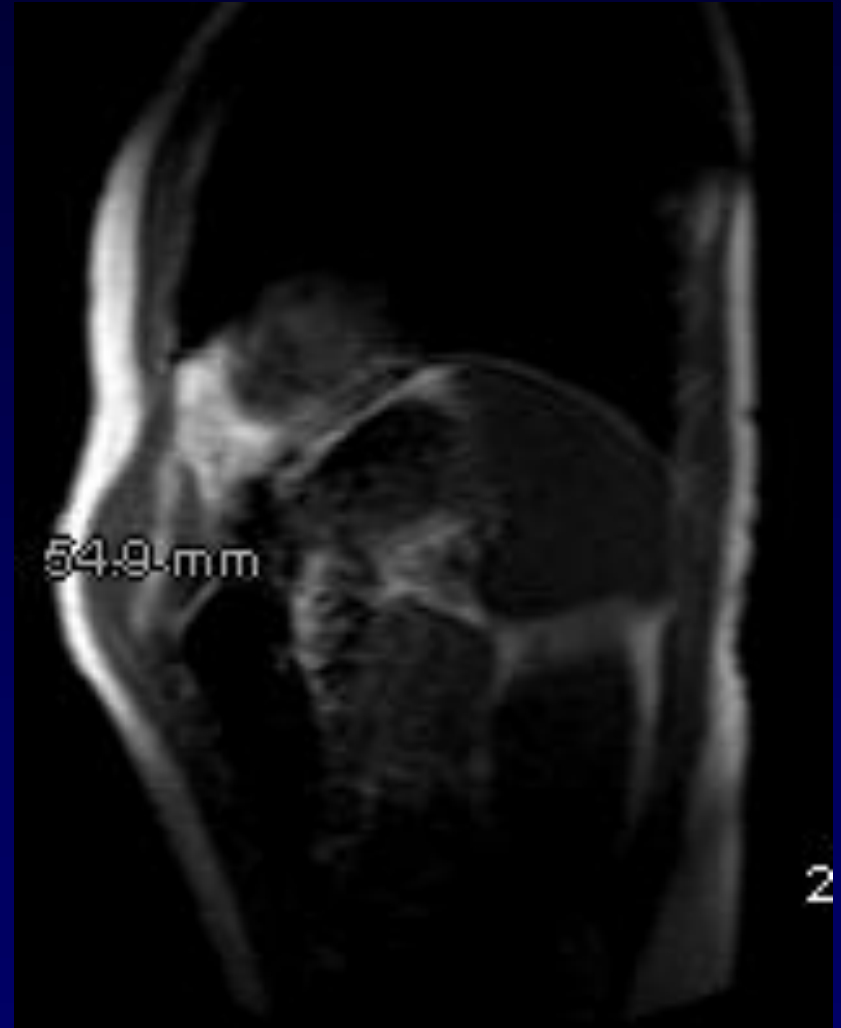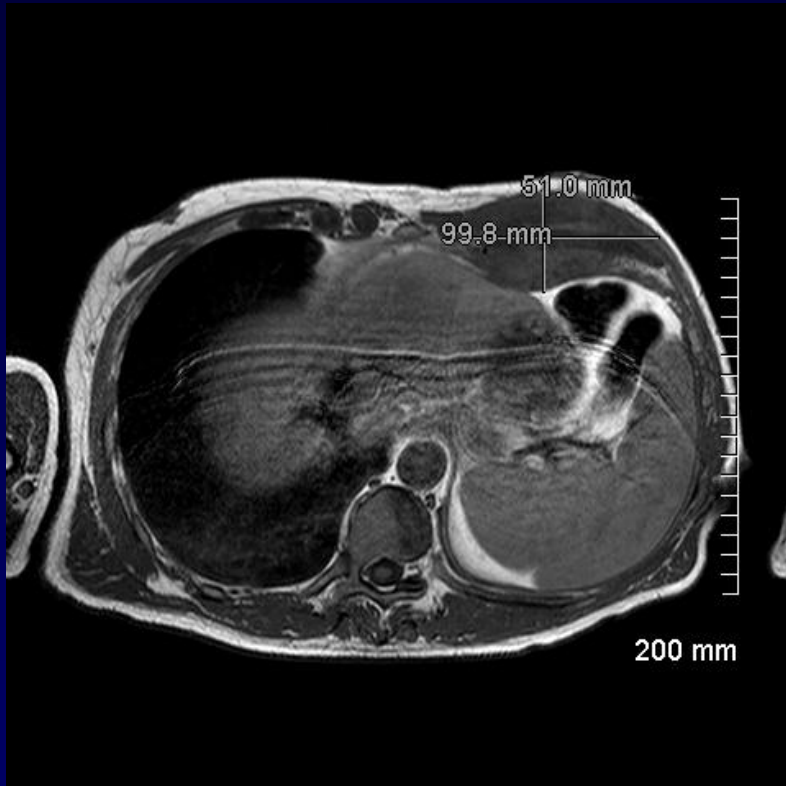


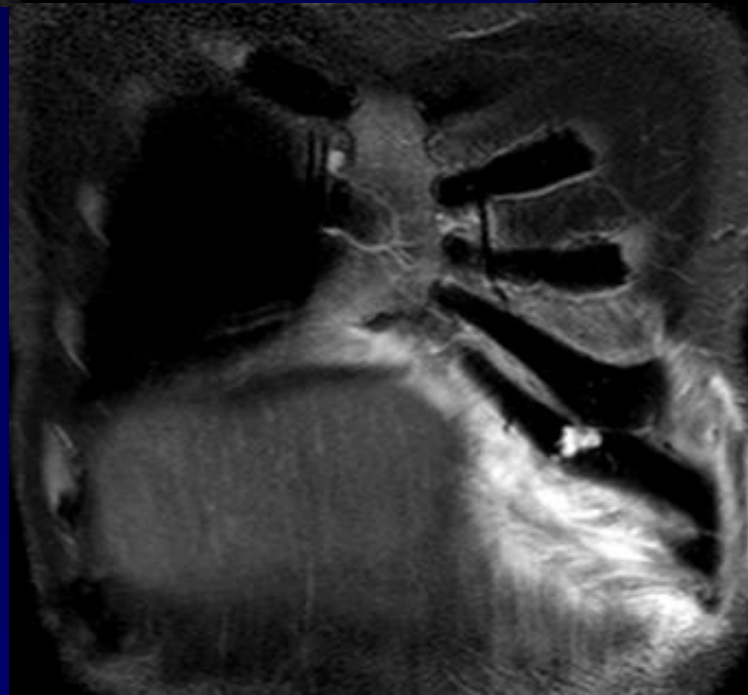
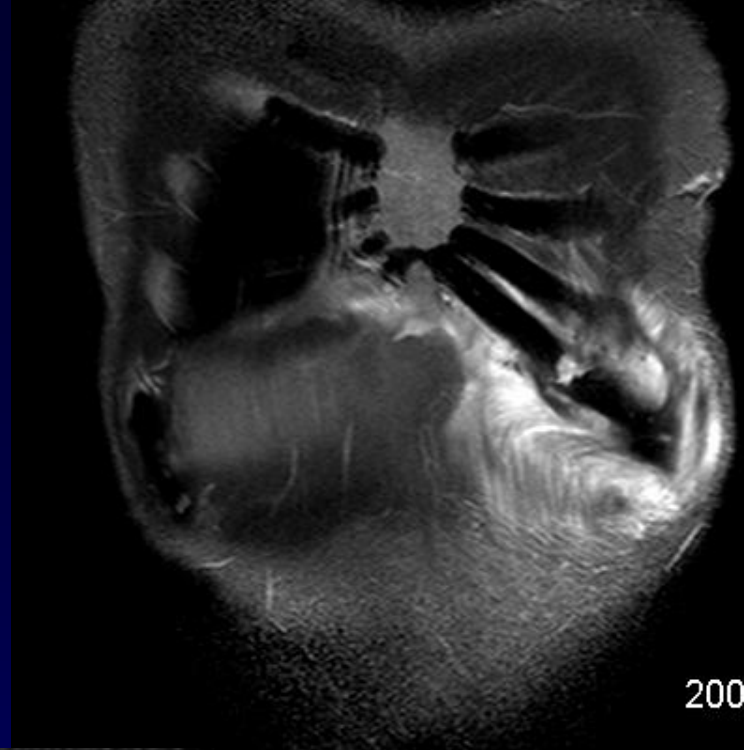

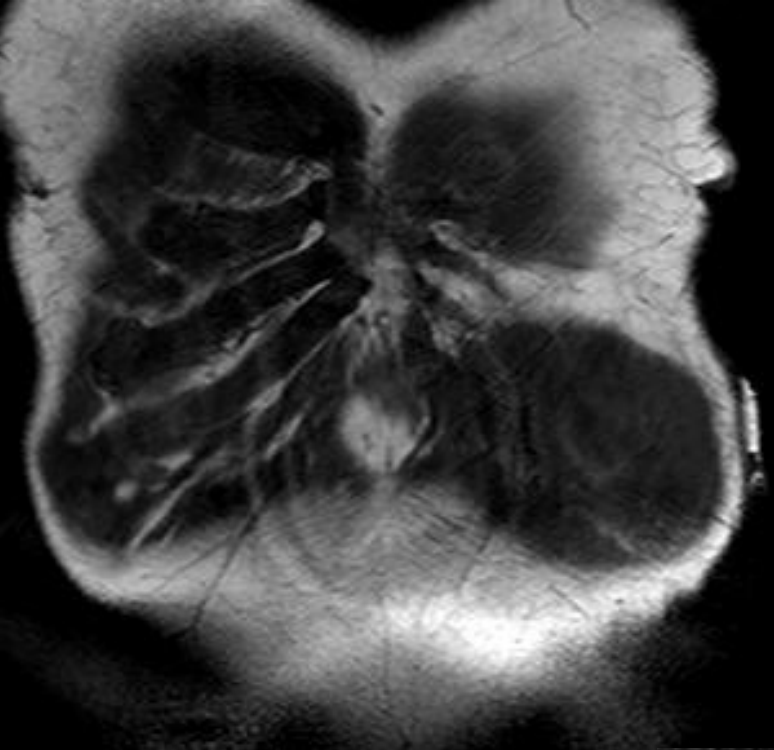




# IRM







**DIAGNOSTIC ?**



# Diagnostic

**Ponction pour écarter Tumeur / VIH**



### CONCLUSION

REMANIEMENTS FIBRO-ADIPEUX ET INFLAMMATOIRES EVOQUANT UN PROCESSUS FIBRO-INFLAMMATOIRE REACTIONNEL OU CICATRICIEL SANS SIGNE DE SPECIFICITE.  
PAS DE SIGNE DE MALIGNITE DANS LA LIMITE DE CES PRELEVEMENTS.



# DIAGNOSTIC

## Fracture cartilage costal et Hématome

